

ANALYSIS OF MASSETER DEFORMATION PATTERNS DURING A MAXIMUM EXERTION CLENCHING IN PATIENTS WITH UNILATERAL CHEWING

A. BUSATO¹, G. BALCONI², V. VISMARA¹, L. BERTELE³, G. GARO⁴, D. DE GREGORIO⁵

A. BUSATO¹, G. BALCONI², V. VISMARA¹, L. BERTELE³, G. GARO⁴, D. DE GREGORIO⁵

¹ Medica Libra, Milano, Italy

² Department of Radiology, Hospital San Raffaele Turro, Milano, Italy

³ Fondazione Apostolo, Merate, Italy

⁴ President and Founder of Siach - The International Society of Surgical Anatomy

⁵ Director of Siach, Aesthetic Surgeon, Perugia, Italy

SUMMARY

Purpose. The aim of the following study is to examine both masseter muscles (left/right) in a group of patients suffering from unilateral chewing during a maximum exertion isometric contraction using the deformation pattern analysis of ultrasound videos and compare them with the results obtained by studying patients with alternate bilateral chewing patterns. **Materials and methods.** This study has been conducted by use of an ultrasound machine and a linear probe which allowed us to record a video (DCM) comprised of 45 frames per second (MicrUs EXT-1H Telemed UAB, Vilnius, Lithuania) and a linear probe (L12-5L40S-3 5-12 MHz 40 mm). The probe was fixed to a brace and the patients were asked to clench their teeth as hard as possible, obtain the muscle's maximum exertion, for 5 seconds three times, with 30 seconds intervals in between. Both right and left masseter muscles were analyzed. We applied to the ultrasound video a dedicated software (Mudy 1.7.7.2 AMID Sulmona Italy) for the analysis of muscle deformation patterns. The total number of patients for this study is 150. Out of this number, 50 belong to Group A, mono lateral chewing on the left side arch, and 50 to Group B, mono lateral chewing on the right side arch. The remains patients belong to Group C, bilateral alternate chewing. The deformation pattern analysis of the skeletal muscles on ultrasound videos allows us to highlight with ease the clear difference in the clenching capabilities and strain management between the dominant masseter and the subordinate masseter in a unilaterally chewing patient. **Results.** In the sample investigated both in Group A and Group B the unilateral chewing is associated with a series of parameters (number, shape, volume, position and orientation of the teeth) and is also associated with the extension of the cutting surface really available.

Key words: unilateral chewing, masseter muscle, ultrasound, strains, pattern of deformations.

Introduction

Unilateral chewing is one of the most frequent alterations of the masticatory cycle. This type of masticatory alteration has many different variables in its execution, depending on the number of shifting movements

that remain, the use of the tongue, the number of teeth used and the location of the occlusal area used to chew food. Unilateral chewing constitutes a considerable risk that could potentially cause dysfunctional syndromes to the masticatory muscles in the best case scenario, to the muscles of the head and neck and to the temporomandibular joints a whole in the worst.

The aim of the following study is to examine both masseter muscles (left/right) in a group of patients suffering from unilateral chewing during a maximum exertion isometric contraction using the deformation pattern analysis of ultrasound videos and compare them with the results obtained by studying patients with alternate bilateral chewing patterns. Both dissection and ultrasound demonstrate that the structure of the masseter muscle is very complex, composed of three distinct parts (Figure 1) and organized in layers (Figure 2): the superficial masseter is formed by two layers (internal and external), the middle masseter has only one layer and the deep masseter has three separate layers (outward, central and inward) (1).

Materials and methods

This study has been constructed by data collected with the following methods and instruments:

1. Ultrasound machine for the recording videoclips of masseter muscles contractions, both left and right.
2. Dedicated software for deformation pattern analysis on ultrasound videos.
3. Intra-oral scanner (3Shape Trios) and chromatic markers.
4. Dedicated software for mapped occlusal surfaces analysis (3Shape Convex).

1. Ultrasound machine for the recording on video of masseter muscles contractions, both left and right

This study has been conducted by use of an ultrasound machine and a linear probe which allowed us to record a video (DCM) comprised of 45 frames per second (MicrUs EXT-1H Telemed UAB, Vilnius, Lithuania) and a linear probe (L12-5L40S-3 5-12 MHz 40 mm). The probe was fixed to a brace and the patients were asked to clench their teeth as hard as possible, obtain the muscle's maximum exertion, for 5 seconds three times, with 30 seconds intervals in between. Both right and left masseter muscles were analyzed. During this

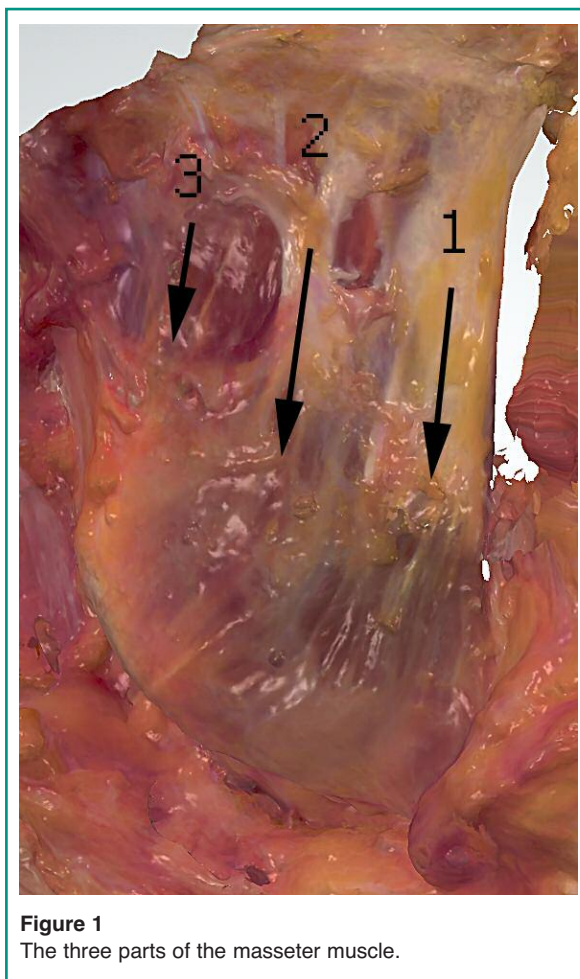


Figure 1
The three parts of the masseter muscle.

procedure, the patients were seating down on a dentists' chair with their head leaning on the headrest. The section of the muscle chosen is that in which the greatest possible expansion and the best view of the muscle layers during the contraction were visible. Said section was then marked on the patient's skin using an L shaped ruler that allows us to mark the bottom edge of the mandible. The procedure was then repeated after inserting two cotton rolls in-between the dental arches.

2. Dedicated software for deformation pattern analysis on ultrasound videos

We applied to the ultrasound video a dedicated software (Mudy 1.7.7.2 AMID Sulmona Italy) for the

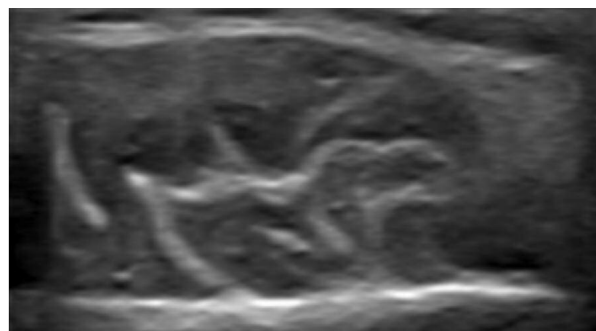
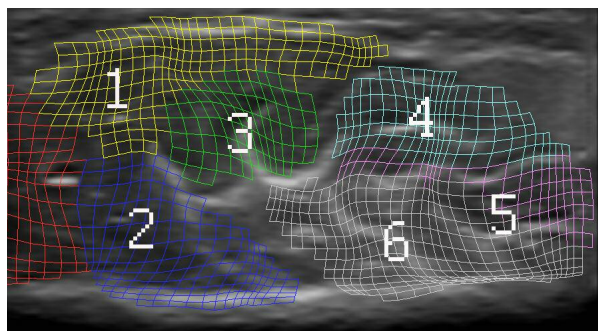


Figure 2
The six layers of the masseter muscle.

analysis of muscle deformation patterns (contraction, dilatation, cross-plane, vertical strain, horizontal strain, vertical shear, horizontal shear, horizontal displacement, vertical displacement). During the contraction, some sections of the muscle dilate and others clench. The strain, shear and displacement patterns describe the recorded phenomena analyzing the movement of the points that form the two-dimensional ultrasound image with respect to two axes, horizontal and vertical. The cross-plane pattern adds the third dimension indicating the movement of those same points in cross-section. The compression and dilatation patterns show the global movement of all of points on the two axes. The qualitative analysis of the deformation patterns was done by contouring the resulting chromatic areas and comparing them to the Region Of Interest (ROI) obtained from the underlying anatomical parts. The quantitative analysis was attained by examining the curves that show the strain in relation to the time. For the achievement of this result six ROI were created, one for each muscle layer (2-17).

3. Intra-oral scanner (3Shape Trios) and chromatic markers

Patients were asked to chew 13 micron blue occlusion test films for 25 seconds as naturally and comfortably as possible after having cleaned all dental surfaces with a weak acid solution. Subsequently the patient underwent a color scan of the dental arches in order to document which parts of the dental surface were

stained with color, and therefore were effectively used during the masticatory process. The test was repeated after a month in order to rule out patients that did not meet the necessary criteria.

An interview on the patient medical history confirmed their belonging to one of the following three groups: right side unilateral chewer (group A), left side unilateral chewer (Group B), bilateral alternate chewer (Group C) (Figure 3).

4. Dedicated software for mapped occlusal surfaces analysis (3Shape Convice)

The occlusal surface used by the patient was measured using a dedicated software (3Shape Convice). Only unilateral chewing patients who used no less than 70% of the total occlusal surface and bilateral chewing patients who used no less than 60% of the total occlusal surface were taken into consideration (Figure 4).

Sample investigated

The total number of patients for this study is 150. Out of this number, 50 belong to Group A, mono lateral chewing on the left side arch, and 50 to Group B, mono lateral chewing on the right side arch. The remains patients belong to Group C, bilateral alternate chewing.

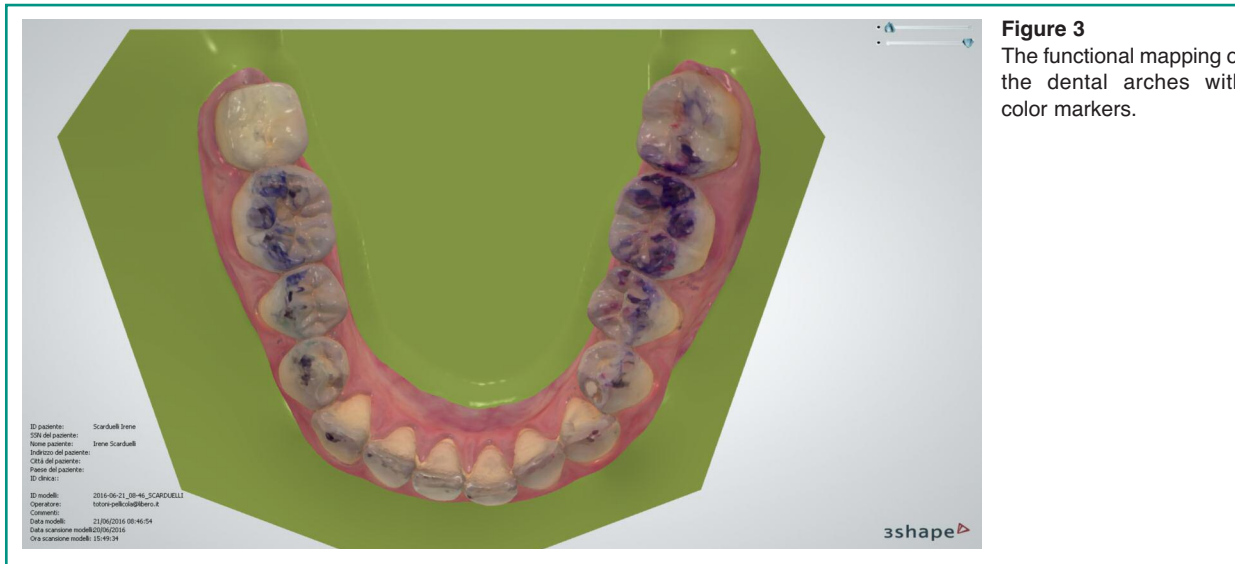

Figure 3
The functional mapping of the dental arches with color markers.

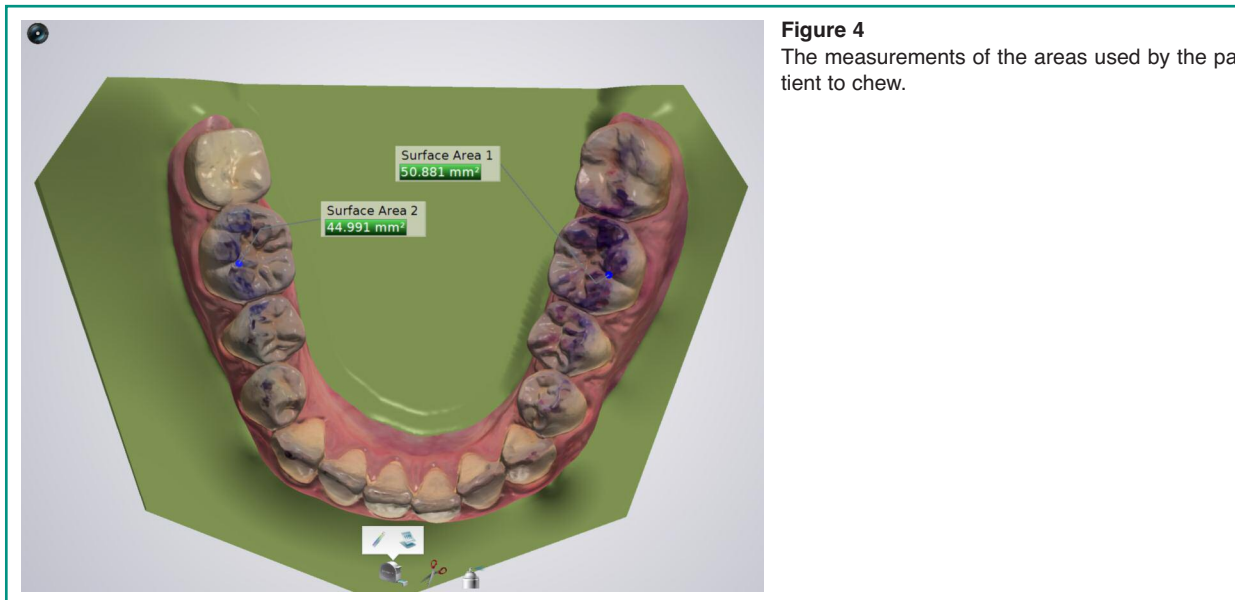


Figure 4
The measurements of the areas used by the patient to chew.

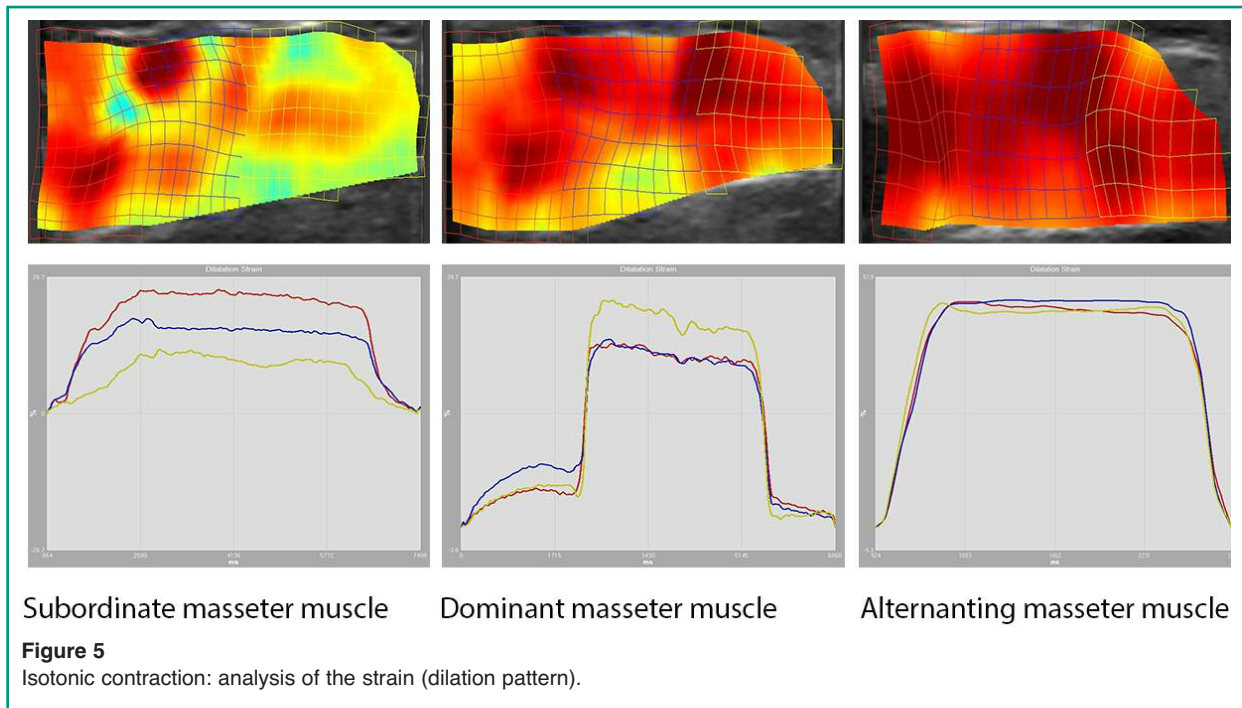
Results

In unilateral chewing patients the deformation pattern analysis allows us to view the radical difference between the “dominant” masseter muscle and the “subordinate” masseter muscle. By “dominant” masseter we refer to the masseter on which the masticatory process take place whereas by “subordinate” we refer to the masseter on the opposite side which does not

perform said activity. In the case of Group C patients, we refer to the masseter muscle as “alternating”.

Dilatation Pattern Analysis (Figure 5)

The dominant masseter presents a constant dilatation pattern that is, on average, almost double that of the



subordinate. In the dominant muscle the dilatation value is around 35% whereas in the subordinate it is less than half that number. The patient feels the greater force of the clenching on the dominant side almost constantly. The subordinate frequently presents an irregular dilatation pattern, making it impossible to recognize and define the three functional areas typical of the masseter muscle discernible in the dominant and alternating masseters. The strain/time curves of the subordinate are clearly the most irregular of the three.

Cross-plane Deformation Pattern (Figure 6)

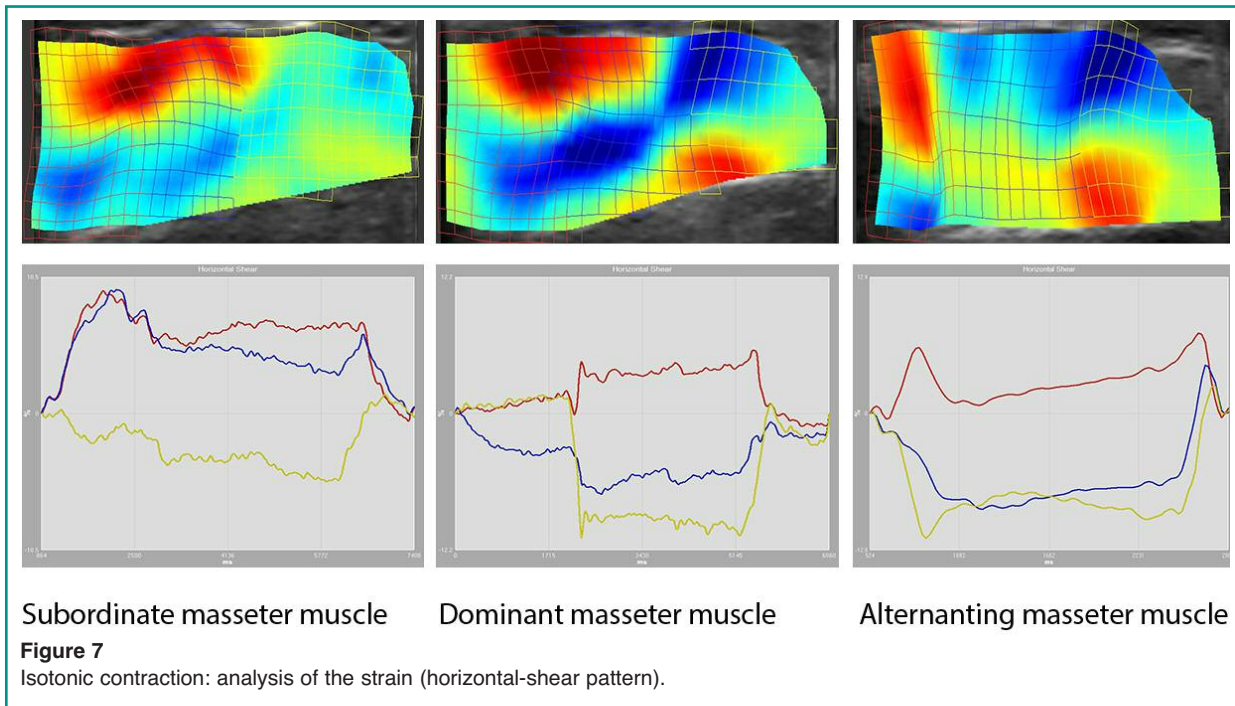
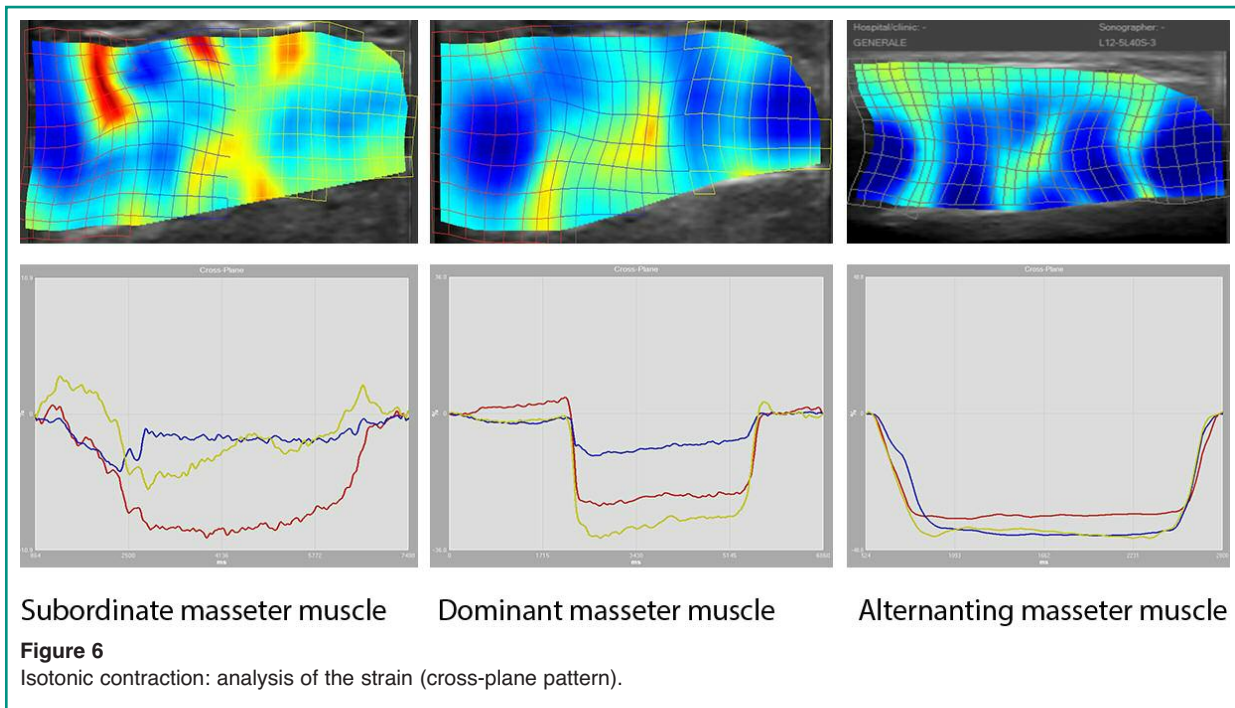
This pattern is one amongst those that appears to be most changed in the subordinate muscle. It features a fragmentation of the concentrated spots in the three sections that constitute the muscle, which sometimes disappear altogether and the image come back as white, and the contemporary disappearance of cross-plane areas with opposite signs. As for the previous pattern, the observed values of the subordinate are almost cut by half. Also noteworthy are the increasing irregularities of the strain/time curves.

Horizontal Shear Pattern (Figure 7)

The management of the twist on the horizontal plane is a control mechanism that is activated regardless the amount of pressure applied when clenching the muscle and in the subordinate masseter's case appears to be steadily compromised, especially in the deep section of the muscle. The loss of the typical horizontal shear cross pattern is a constant recurrence for the subordinate masseter.

Horizontal Displacement Pattern (Figure 8)

During an isometric contraction, the anterior part of the muscle (superficial masseter) and the posterior part (deep masseter) suffer a movement of opposite degree in a dorsal-ventral direction. The middle masseter appears scarcely active in this pattern. As for the subordinate masseter we can observe that also in this pattern a part of the muscle suffers from a loss of mobility, normally in the deep area (posterior).



Vertical Displacement Pattern (Figure 9)

Shows the relative movement in the mediolateral di-

rection, to be interpreted as opposite in relation to the observations from the ultrasound video of the previous case. The subordinate masseter once again suffers from a constant alteration in terms of relative and absolute mobility.

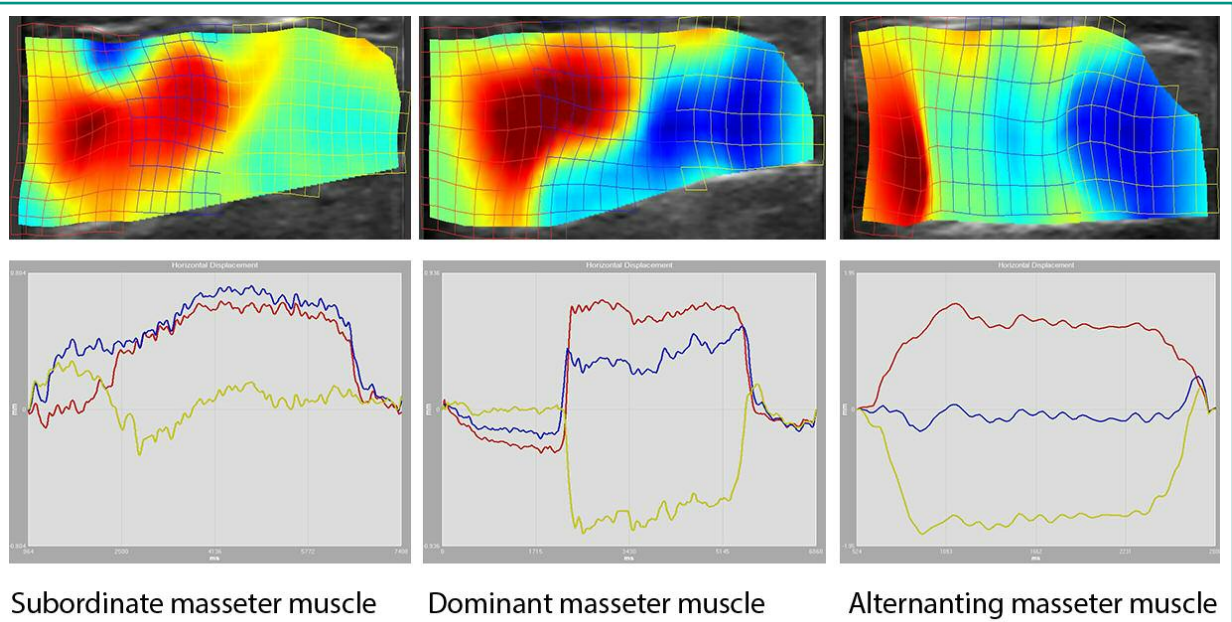


Figure 8
Isotonic contraction: analysis of the strain (horizontal displacement pattern).

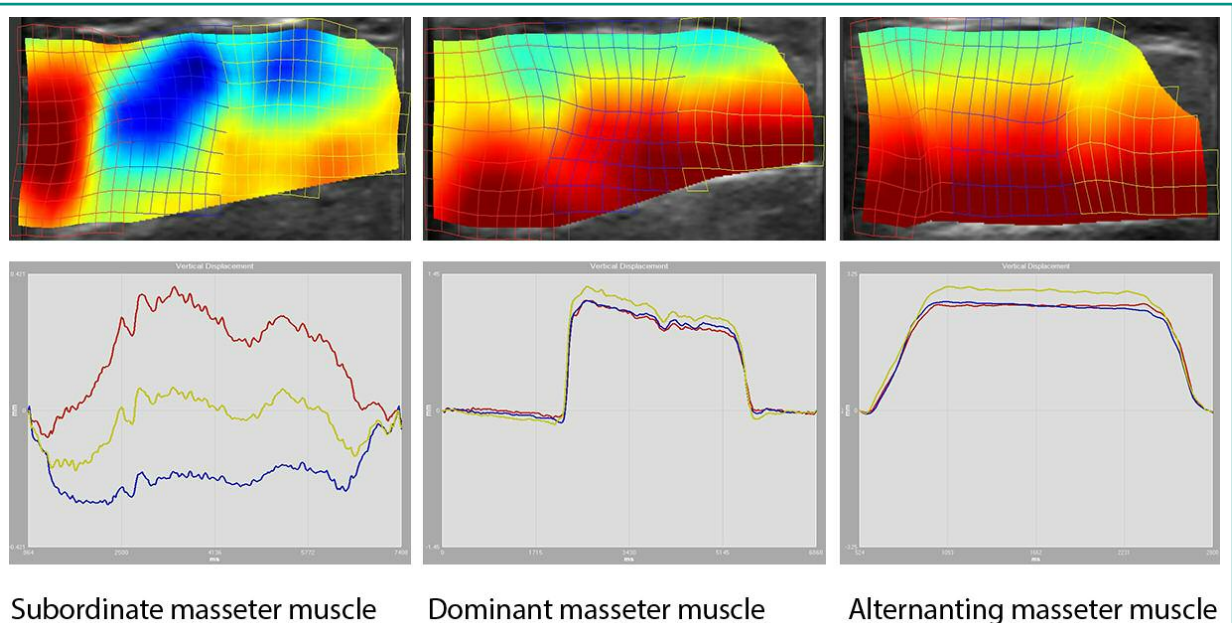


Figure 9
Isotonic contraction: analysis of the strain (vertical displacement pattern).

Discussion

The dominant masseter normally displays three defined functional areas as described by the literature

and as observed during the anatomical dissection. The dilatation pattern is, on average, equal to or higher than 30% of the overall capabilities of the muscle. The curves appear to be fairly continuous and regular with a predominance of the middle masseter and of the cen-

tral layer of the deep masseter. The dilatation capabilities of the muscle are incremented by about 10% in 65% of cases by the addition of the cotton rolls. The cross-pattern of the dominant masseter is generally negative with three prominent areas visible. The deformation patterns of the dominant masseter are rather similar to those of the alternating masseters.

On the other hand, the subordinate masseter usually presents a lack of functional areas (64% of cases) and, when present, the three are poorly defined. The dilatation pattern is often under 15% (75% of cases) and the cross-plane pattern is positive or both positive and negative at the same time. The curves appear as discontinuous and irregular. The patterns of the subordinate masseter are very different both qualitatively and quantitatively from the twisting control mechanisms of bilateral chewers. The addition of cotton rolls follows a modest improvement in less than 40% of cases. In the other 60% the cotton rolls either worsen the performance of the muscle or leave it unvaried.

In patients from Group C both masseters, left and right, display similar characteristics to the dominant masseter of the other groups allowing us to dismiss the need to classify one of them as subordinate.

The deformation pattern analysis of the skeletal muscles on ultrasound videos allows us to highlight with ease the clear difference in the clenching capabilities and strain management between the dominant masseter and the subordinate masseter in a unilaterally chewing patient. This is of paramount importance also in orthodontics and implantology (18-68,69 Scarno, 2007 #1896,70). In the sample investigated both in Group A and Group B the unilateral chewing is associated with a series of parameters (number, shape, volume, position and orientation of the teeth) and is also associated with the extension of the cutting surface really available. Dental fillings, prosthetic crowns, seals and usury derived from fatigue of the occlusal surface can sensibly reduce the cutting surface available. Moreover, the performance of the subordinate masseter in a considerable amount of cases (60%) does not experiment any improvement after the insertion of cotton rolls, thus indicating the predictable uselessness or even harmfulness of custom made devices, such as dental guards (for night and/or day use), used for the treatment of dysfunctions and pathologies presumably caused by unilateral chewing, which would

then have nothing to do with parafunctional issues or postural anomalies of the mandible.

References

1. Busato A, Balconi G, Vismara V, Bertele L, Tonti G, Pedrizzetti G. Strain Analysis of Masseter Muscle by Ultrasound. *J Biol Regul Homeost Agents*. 2015;29:74-81.
2. Rocha CP, Croci CS, Caria PH. Is there relationship between temporomandibular disorders and head and cervical posture? A systematic review. *J Oral Rehabil*. 2013;40:875-81.
3. Singh A. Optic Flow Computation: A Unified Perspective. Place: IEEE Comput. Soc. 1992.
4. Barron JL, Fleet DJ, Beauchemin SS. Performance of optical flow techniques. *International Journal of Computer Vision*. 1994;12:43-77.
5. Bohs LN, Geiman BJ, Anderson ME, Gebhart SC, Trahey GE. Speckle tracking for multi-dimensional flow estimation. *Ultrasonics*. 2000;38:369-75.
6. Malpica N, Santos A, Zuluaga MA, Ledesma MJ, Perez E, Garcia-Fernandez MA, Desco M. Tracking of regions-of-interest in myocardial contrast echocardiography. *Ultrasound Med Biol*. 2004;30:303-9.
7. Leitman M, Lysyansky P, Sidenko S, et al. Two-dimensional strain-a novel software for realtime quantitative echocardiographic assessment of myocardial function. *J Am Soc Echocardiogr*. 2004;17:1021-29.
8. Vannan MA, Pedrizzetti G, Li P, et al. Effect of cardiac resynchronization therapy on longitudinal and circumferential left ventricular mechanics by velocity vector imaging: description and initial clinical application of a novel method using high-frame rate B-mode echocardiographic images. *Echocardiography*. 2005;22:826-30.
9. Pedrizzetti G, Sengupta S, Caracciolo G, et al. Three-dimensional principal strain analysis for characterizing subclinical changes in left ventricular function. *J Am Soc Echocardiogr*. 2014;27:1041-50 e1.
10. Loram ID, Maganaris CN, Lakie M. Use of ultrasound to make noninvasive in vivo measurement of continuous changes in human muscle contractile length. *J Appl Physiol* (1985). 2006;100:1311-23.
11. Yoshii Y, Villarraga HR, Henderson J, Zhao C, An KN, Amadio PC. Speckle tracking ultrasound for assessment of the relative motion of flexor tendon and subsynovial connective tissue in the human carpal tunnel. *Ultrasound Med Biol*. 2009;35:1973-81.
12. Peolsson M, Lofstedt T, Vogt S, Stenlund H, Arndt A, Trygg J. Modelling human musculoskeletal functional movements using ultrasound imaging. *BMC Med Im-*

- aging. 2010;10:9.
13. Korstanje JW, Schreuders TR, van der Sijde J, Hovius SE, Bosch JG, Selles RW. Ultrasonographic assessment of long finger tendon excursion in zone v during passive and active tendon gliding exercises. *J Hand Surg Am.* 2010;35:559-65.
 14. Darby J, Hodson-Tole EF, Costen N, Loram ID. Automated regional analysis of B-mode ultrasound images of skeletal muscle movement. *J Appl Physiol (1985).* 2012;112:313-27.
 15. Mor-Avi V, Lang RM, Badano LP, et al. Current and evolving echocardiographic techniques for the quantitative evaluation of cardiac mechanics: ASE/EAE consensus statement on methodology and indications endorsed by the Japanese Society of Echocardiography. *Eur J Echocardiogr.* 2011;12:167-205.
 16. Pedrizzetti G, Kraigher-Krainer E, De Luca A, et al. Functional strain-line pattern in the human left ventricle. *Phys Rev Lett.* 2012;109:048103.
 17. Lopata RG, van Dijk JP, Pillen S, et al. Dynamic imaging of skeletal muscle contraction in three orthogonal directions. *J Appl Physiol (1985).* 2010;109:906-15.
 18. Lucchese A, Carinci F, Saggese V, Lauritano D. Orthodontic tooth movement and distraction osteogenesis. *European Journal of Inflammation.* 2012;10:49-54.
 19. Lucchese A, Carinci F, Brunelli G. Skeletal effects induced by twin block in therapy of class II malocclusion. *European Journal of Inflammation.* 2012;10:83-87.
 20. Mancini GE, Carinci F, Zollino I, Avantaggiato A, Lucchese A, Puglisi P, Brunelli G. Lingual orthodontic technique: A case series analysis. *European Journal of Inflammation.* 2011;9:47-51.
 21. Mancini GE, Carinci F, Zollino I, Avantaggiato A, Puglisi P, Caccianiga G, Brunelli G. Effectiveness of self-ligating orthodontic treatment. *European Journal of Inflammation.* 2011;9:53-58.
 22. Mancini GE, Carinci F, Avantaggiato IZ, Puglisi P, Caccianiga G, Brunelli G. Simplicity and reliability of invisalign® system. *European Journal of Inflammation.* 2011;9:43-52.
 23. Avantaggiato A, Zollino I, Carinci F. Impact of orthodontic treatment on crestal bone resorption in periodontally compromised patients: A case series. *Acta Stomatologica Croatica.* 2010;44:188-94.
 24. Busato A, Vismara V, Bertele L, Zollino I, Carinci F. Relation between disk/condyle incoordination and joint morphological changes: A retrospective study on 268 TMJs. *Oral Surgery, Oral Medicine, Oral Pathology, Oral Radiology and Endodontology.* 2010;110
 25. El Haddad E, Lauritano D, Carinci F. Interradicular septum as guide for pilot drill in postextractive implantology: a technical note. *J Contemp Dent Pract.* 2015;16:81-4.
 26. Andreasi Bassi M, Lopez MA, Confalone L, Carinci F. Hydraulic sinus lift technique in future site development: clinical and histomorphometric analysis of human biopsies. *Implant Dent.* 2015;24:117-24.
 27. Lopez MA, Andreasi Bassi M, Confalone L, Carinci F. Maxillary sinus floor elevation via crestal approach: the evolution of the hydraulic pressure technique. *J Craniofac Surg.* 2014;25:e127-32.
 28. Lucchese A, Carinci F, Saggese V, Lauritano D. Immediate loading versus traditional approach in functional implantology. *European Journal of Inflammation.* 2012;10:55-58.
 29. Danza M, Paracchini L, Carinci F. Tridimensional finite element analysis to detect stress distribution in implants. *Dental Cadmos.* 2012;80:598-602.
 30. Fanali S, Carinci F, Zollino I, Brugnati C, Lauritano D. One-piece implants installed in restored mandible: a retrospective study. *European Journal of Inflammation.* 2012;10:19-23.
 31. Scarano A, Murmura G, Carinci F, Lauritano D. Immediately loaded small-diameter dental implants: evaluation of retention, stability and comfort for the edentulous patient. *European Journal of Inflammation.* 2012;10:19-23.
 32. Fanali S, Carinci F, Zollino I, Brugnati C, Lauritano D. A retrospective study on 83 one-piece implants installed in resorbed maxillae. *European Journal of Inflammation.* 2012;10:55-58.
 33. Scarano A, Perrotti V, Carinci F, Shibli JA. Removal of a migrated dental implant from the maxillary sinus after 7 years: A case report. *Oral and Maxillofacial Surgery.* 2011;15:239-43.
 34. Scarano A, Piattelli A, Assenza B, Carinci F, Donato LD, Romani GL, Merla A. Infrared thermographic evaluation of temperature modifications induced during implant site preparation with cylindrical versus conical drills. *Clinical Implant Dentistry and Related Research.* 2011;13:319-23.
 35. Scarano A, Piattelli A, Assenza B, Sollazzo V, Lucchese A, Carinci F. Assessment of pain associated with insertion torque of dental implants. A prospective, randomized-controlled study. *International Journal of Immunopathology and Pharmacology.* 2011;24:65-69.
 36. Traini T, Danza M, Altavilla R, et al. Histomorphometric evaluation of an implant retrieved from human maxilla after 13 years. *International Journal of Immunopathology and Pharmacology.* 2011;24:25-30.
 37. Danza M, Grecchi F, Zollino I, Casadio C, Carinci F. Spiral implants bearing full-arch rehabilitation: Analysis of clinical outcome. *Journal of Oral Implantology.* 2011;37:447-55.
 38. Danza M, Zollino I, Avantaggiato A, Lucchese A, Carinci F. Distance between implants has a potential impact of crestal bone resorption. *Saudi Dental Journal.* 2011;23:129-33.
 39. Scarano A, Murmura G, Sinjiari B, Sollazzo V, Spinelli G, Carinci F. Analysis and structural examination of screw loosening in oral implants. *International Journal of Immunopathology and Pharmacology.* 2011;24:77-81.
 40. Scarano A, Murmura G, Sinjiari B, Assenza B, Sollazzo

- V, Spinelli G, Carinci F. Expansion of the alveolar bone crest with ultrasonic surgery device: Clinical study in mandible. *International Journal of Immunopathology and Pharmacology*. 2011;24:71-75.
41. Traini T, Danza M, Zollino I, et al. Histomorphometric evaluation of an immediately loaded implant retrieved from human mandible after 2 years. *International Journal of Immunopathology and Pharmacology*. 2011;24:31-36.
 42. Carinci F, Danza M. Clinical outcome of implants inserted in piezo split alveolar ridges: A pilot study. In: *Perspectives on Clinical Dentistry*. 2011:29-30.
 43. Danza M, Zollino I, Guidi R, Carinci F. Computer planned implantology: Analysis of a case series. In: *Perspectives on Clinical Dentistry*. 2011:287-300.
 44. Grecchi F, Pagliani L, Mancini GE, Zollino I, Carinci F. Implant treatment in grafted and native bone in patients affected by ectodermal dysplasia. *Journal of Craniofacial Surgery*. 2010;21:1776-80.
 45. Danza M, Carinci F. Flapless surgery and immediately loaded implants: a retrospective comparison between implantation with and without computer-assisted planned surgical stent. *Stomatologija*. 2010;12:35-41.
 46. Grecchi F, Zingari F, Bianco R, Zollino I, Casadio C, Carinci F. Implant rehabilitation in grafted and native bone in patients affected by ectodermal dysplasia: evaluation of 78 implants inserted in 8 patients. *Implant Dent*. 2010;19:400-8.
 47. Grecchi F, Mancini G, Parafioriti A, Mineo G, Zollino I, Pricolo A, Carinci F. Ectodermal dysplasia treated with one-step surgical rehabilitation: a case report. *Singapore Dent J*. 2010;31:9-14.
 48. Danza M, Quaranta A, Carinci F, Paracchini L, Pompa G, Voza I. Biomechanical evaluation of dental implants in D1 and D4 bone by Finite Element Analysis. *Minerva stomatologica*. 2010;59:305-13.
 49. Carinci F, Brunelli G, Franco M, Viscioni A, Rigo L, Guidi R, Strohmenger L. A retrospective study on 287 implants installed in resorbed maxillae grafted with fresh frozen allogeneous bone. *Clin Implant Dent Relat Res*. 2010;12:91-8.
 50. Viscioni A, Rigo L, Franco M, Brunelli G, Avantaggiato A, Sollazzo V, Carinci F. Reconstruction of severely atrophic jaws using homografts and simultaneous implant placement: a retrospective study. *J Oral Implantol*. 2010;36:131-9.
 51. Danza M, Riccardo G, Carinci F. Bone platform switching: a retrospective study on the slope of reverse conical neck. *Quintessence Int*. 2010;41:35-40.
 52. Degidi M, Piattelli A, Iezzi G, Carinci F. Wide-diameter implants: Analysis of clinical outcome of 304 fixtures. *Journal of Periodontology*. 2007;78:52-58.
 53. Degidi M, Piattelli A, Gehrke P, Felice P, Carinci F. Five-year outcome of 111 immediate nonfunctional single restorations. *J Oral Implantol*. 2006;32:277-85.
 54. Degidi M, Piattelli A, Gehrke P, Carinci F. Clinical outcome of 802 immediately loaded 2-stage submerged implants with a new grit-blasted and acid-etched surface: 12-month follow-up. *Int J Oral Maxillofac Implants*. 2006;21:763-8.
 55. Danza M, Fromovich O, Guidi R, Carinci F. The clinical outcomes of 234 spiral family implants. *J Contemp Dent Pract*. 2009;10:E049-56.
 56. Scarano A, Piattelli M, Carinci F, Perrotti V. Removal, after 7 years, of an implant displaced into the maxillary sinus. A clinical and histologic case report. *Journal of Osseointegration*. 2009;1:35-40.
 57. Carinci F, Brunelli G, Danza M. Platform switching and bone platform switching. *J Oral Implantol*. 2009;35:245-50.
 58. Grecchi F, Danza M, Bianco R, Parafioriti A, Carinci F. Computer planned implant-orthognathic rehabilitation: a case of one step surgical procedure with implants insertion, Le Fort I advancement, grafting and immediate loading. *J Osseointegration*. 2009;3.
 59. Franco M, Rigo L, Viscione A, et al. CaPO4 blasted implants inserted into iliac crest homologue frozen grafts. *The Journal of oral implantology*. 2009;35:176-80.
 60. Danza M, Guidi R, Carinci F. Comparison Between Implants Inserted Into Piezo Split and Unsplit Alveolar Crests. *Journal of Oral and Maxillofacial Surgery*. 2009;67:2460-65.
 61. Grecchi F, Zollino I, Parafioriti A, Mineo G, Pricolo A, Carinci F. One-step oral rehabilitation by means of implants' insertion, Le Fort I, grafts, and immediate loading. *J Craniofac Surg*. 2009;20:2205-10.
 62. Viscioni A, Franco M, Rigo L, Guidi R, Brunelli G, Carinci F. Implants inserted into homografts bearing fixed restorations. *Int J Prosthodont*. 2009;22:148-54.
 63. Degidi M, Piattelli A, Felice P, Carinci F. Immediate functional loading of edentulous maxilla: a 5-year retrospective study of 388 titanium implants. *J Periodontol*. 2005;76:1016-24.
 64. Franco M, Viscioni A, Rigo L, Guidi R, Zollino I, Avantaggiato A, Carinci F. Clinical outcome of narrow diameter implants inserted into allografts. *J Appl Oral Sci*. 2009;17:301-6.
 65. Danza M, Guidi R, Carinci F. Spiral family implants inserted in postextraction bone sites. *Implant Dent*. 2009;18:270-8.
 66. Viscioni A, Franco M, Rigo L, Guidi R, Spinelli G, Carinci F. Retrospective study of standard-diameter implants inserted into allografts. *J Oral Maxillofac Surg*. 2009;67:387-93.
 67. Carinci F, Brunelli G, Zollino H, et al. Mandibles grafted with fresh-frozen bone: An evaluation of implant outcome. *Implant Dentistry*. 2009;18:86-95.
 68. Carinci F, Guidi R, Franco M, Viscioni A, Rigo L, De Santis B, Tropina E. Implants inserted in fresh-frozen bone: a retrospective analysis of 88 implants loaded 4 months after insertion. *Quintessence Int*. 2009;40:413-9.
 69. Franco M, Tropina E, De Santis B, Viscioni A, Rigo L, Guidi R, Carinci F. A 2-year follow-up study on stan-

- standard length implants inserted into alveolar bone sites augmented with homografts. *Stomatologija*. 2008;10:127-32.
70. Scarano A, Carinci F, Quaranta A, Iezzi G, Piattelli M, Piattelli A. Correlation between implant stability quotient (ISQ) with clinical and histological aspects of dental implants removed for mobility. *International journal of immunopathology and pharmacology*. 2007;20:33-36.

Correspondence to:
Antonio Busato, DMD
Medica Libra
Via Gian Girolamo Savoldo 3
Milano (MI), Italy
Phone/fax: +39.02.6437937
E-mail: info@medica-libra.it